

OSTEOARTHRITIS IN THE TEMPOROMANDIBULAR JOINT AND KNEE JOINT: A  
MACROSCOPIC STUDY OF CADAVER SPECIMENS

By

Jeremy James

Bachelor of Science – Exercise Science and Japanese  
Brigham Young University  
2013

Bachelor of Science – Biology  
Utah Valley University  
2016

Doctor of Dental Medicine  
University of Nevada, Las Vegas  
2021

A thesis submitted in partial fulfillment  
of the requirements for the

Master of Science – Oral Biology

School of Dental Medicine  
The Graduate College

University of Nevada, Las Vegas  
May 2024

Copyright by Jeremy James, 2024

All Rights Reserved



## Thesis Approval

The Graduate College  
The University of Nevada, Las Vegas

March 5, 2024

This thesis prepared by

Jeremy James

entitled

Osteoarthritis in the Temporomandibular Joint and Knee Joint: A Macroscopic Study of Cadaver Specimens

is approved in partial fulfillment of the requirements for the degree of

Master of Science – Oral Biology  
School of Dental Medicine

Jessica Immonen, Ph.D.  
*Examination Committee Chair*

Alyssa Crittenden, Ph.D.  
*Vice Provost for Graduate Education &  
Dean of the Graduate College*

Karl Kingsley, Ph.D.  
*Examination Committee Member*

Brian Chrzan, Ph.D.  
*Examination Committee Member*

Linh Nguyen, Ph.D.  
*Examination Committee Member*

Erika Marquez, Ph.D.  
*Graduate College Faculty Representative*

## Abstract

In this study, thirty-one TMJs and twenty-eight knee joints were dissected from seventeen cadaveric subjects aged 69 to 95. Degenerative/osteoarthritic changes on the mandibular condyles, mandibular fossae, and femoral condyles were evaluated macroscopically and assigned a score on a disease severity scale (DSS) from 0 signifying “normal cartilage” to 4 signifying “severe OA”. Osteoarthritic changes were found in all TMJ and knee specimens. The average mandibular condyle DSS score was  $2.68 \pm 0.96$ , while the average mandibular fossa score was  $2.90 \pm 0.76$ ; this difference in scores was significant ( $P = 0.035$ ). Additionally, the mandibular fossa was equally or more severely degenerated than the mandibular condyle in 87% of the TMJ specimens. The majority of degenerative changes observed in this study were found along the lateral aspects of the TMJ components. No statistically significant correlation was found between TMJ OA severity and subject age or TMJ OA severity and subject gender.

While studies have been published comparing OA in the TMJ to OA in other joints, to the authors’ knowledge the work presented here is the first to directly compare macroscopic degenerative changes in the TMJ to those in the knee joints of the same subjects. The DSS scores of the femoral condyles were found to be statistically comparable to those of the mandibular fossa, while the mandibular condyles were found to be less degenerated than the femoral condyles ( $P=0.04$ ). Previous studies have shown a weak correlation between degenerative changes in the metatarsophalangeal joints and the TMJs in the same subjects, but no significant correlation or mixed results when comparing the TMJs to the hand or sternoclavicular joints. It is therefore hypothesized that the statistically comparable degeneration found in this study in the temporomandibular and knee joints is due to their load-bearing functions.

## Acknowledgments

I am very grateful to Dr. Jessica Immonen for her amazing leadership and mentorship throughout this research project. I would also like to thank my committee members; Dr. Linh Nguyen, Dr. Karl Kingsley, Dr. Brian Chrzan, and Dr. Erika Marquez for their assistance and support. Lastly, I would like to thank my wife Nicole for continually supporting me in my academic journey.

# Table of Contents

Abstract .....	iii
Acknowledgments.....	iv
Table of Contents .....	v
List of Tables .....	vii
List of Figures .....	viii
Chapter 1: Introduction .....	1
Research Questions .....	6
Chapter 2: Previously Published Material .....	7
Abstract .....	7
Introduction.....	8
Methodology .....	10
Results.....	16
Discussion .....	23
Acknowledgements.....	29
References.....	30
Chapter 3: Discussion .....	34
Chapter 4: Conclusions .....	40
Answers to Research Questions.....	40

Limitations .....	41
Future Work .....	42
Conclusion .....	43
Appendix A.....	45
References.....	46
Curriculum Vitae .....	55

## List of Tables

<b>Table 1.</b> Identifying number, sex, age of death, and primary cause of death for the 16 cadaveric donors composing the specimen pool.....	11
<b>Table 2.</b> Scale modified from Kovler et al. (2004) to be implemented in the knee joint and the TMJ.....	14
<b>Table 3.</b> Comparison of grading scales used for evaluating levels of joint degeneration in published studies.....	34
<b>Table 4.</b> Autopsy-based studies reporting prevalence of TMJ OA in older adults .....	35



## List of Figures

<b>Figure 1.</b> This figure represents sample images for Grade 1-Grade 4 OA disease severity on the TMJ condyle (Figure 1A) and the TMJ articular fossa (Figure 1B). Grade 0 OA findings have yet to be dissected in this research program likely based on the youngest donor’s age (69 years old).....	17
<b>Figure 2.</b> Sample image of a stellate fracture on the medial tibial plateau.....	18
<b>Figure 3.</b> This figure represents similar gross findings of OA in the knee joint and the TMJ on a single 91-year-old donor.....	22
<b>Figure 4.</b> Figure demonstrates the variations of the mandibular condyle drawn in schematic and by representative photographs from the donor pool.....	25
<b>Figure 5.</b> Images from Immonen et al. 2024 [41] demonstrate example mandibular fossae with preferential degeneration on the lateral side of the articular eminence (A) or equivalent wear across the entire articular eminence (B).....	38

## Chapter 1: Introduction

The temporomandibular joint (TMJ) is a bilateral synovial joint connecting the mandibular condyle and the glenoid fossa (mandibular fossa) of the temporal bone. The joint is unique in that its articular surfaces are lined with fibrocartilage opposed to hyaline cartilage like other synovial joints. The articular disc forms two separate joint compartments. The capsular attachments of the upper compartment are more lax based on the addition of collateral ligaments that reinforce the lower joint compartment. Sliding and translational movements take place in the upper joint compartment while hinge-type movements occur in the lower joint compartment. Lateral movements generally take place unilaterally, with minimal lateral movement of the entire mandible (termed Bennett shift) [1].

The National Institute of Dental and Craniofacial Research estimates that temporomandibular joint disorders (TMJDs) affect approximately 5 to 12% of the population with an estimated annual cost of \$4 billion [2]. However, a recent systematic review and meta-analysis estimates that the prevalence of TMJD may be higher: affecting 31% of adults and 11% of children and adolescents [3]. TMJ osteoarthritis (OA) is just one of the many conditions classified as TMJDs and is defined as “a degenerative disorder involving the joint characterized by deterioration of articular tissue with concomitant osseous changes in the condyle and/or articular eminence” [4].

Studies of TMJ OA using cadaveric joints started in the 1930's with two articles published in German by Bauer and Steinhardt [5]. In his English 1941 publication, Bauer qualitatively described his findings from macro- and microscopic evaluation of 42 TMJs, including the 32 joints of his 1932 study. The TMJs were taken from 25 subjects ranging in age from 3 to 81 years and Bauer noted that “traumatic changes” increased with age and affected

“the cartilage of the condyle, the articular tubercle, the mandibular fossa, and the disk structure” [6]. He also postulated that the formation of degenerative “lesions” correlated with loss of lateral dentition or edentulousness.

Macalister (1954) examined 69 TMJs from subjects aged 16 to 86 with most subjects being over the age 50. Fifty-nine percent of the TMJs examined in the study were from subjects who were edentulous. The author found histopathological changes ranging from “surface flaking and blistering of the articular tissue to splitting and fissuring of the thickened fibrocartilaginous layer” in 60 of the 69 TMJs evaluated with the most advanced lesions being found on joints from edentulous and/or female subjects [7]. Additionally, as in Bauer’s study, Macalister found degenerative lesions appeared to increase with age.

In what is likely still the largest scale autopsy-based study of TMJs to date, Blackwood (1963) evaluated 530 TMJs from subjects of all ages to assess degeneration from rheumatoid arthritis and osteoarthritis. Only 10 of the 530 joints were from subjects with rheumatoid arthritis, leaving the remaining 520 for assessment of osteoarthritic changes. The author found osteoarthritic changes to be rare before the age of 40 after which degeneration “increased proportionately with age...and show[ed] a preponderance in the female sex” [8]. Four hundred of the TMJs in the study were from subjects over the age of 40 with osteoarthritic changes being found in 40% of the joints, however, 80% of those subjects were also edentulous. Blackwood suggested both in his 1963 and 1969 publications of this study that osteoarthritic lesions appear first over the posterior articular surface of condyle before widening to include the entire condylar head. He hypothesized that the “roughening” of the condyle then disrupts the articular disc causing osteoarthritic changes in first the disc and later the mandibular fossa [9].

Oberg et al. (1971) examined 115 right TMJs of both genders aged 1 day to 93 years with varying levels of dentition. The terms “arthrosis” and “osteoarthritis” were used interchangeably in the publication. The authors found that “arthritic changes...were rare in individuals below 40 years, but relatively common (27%) in ages above 39 years” and “the frequency of arthritic changes was not higher in the oldest individuals than in those between 40 and 59 years” [5]. They also found that TMJ OA was more frequent in females (nearly significant,  $p < 0.05$  by  $\chi^2$  test) and statistically more prevalent in subjects with extensive loss of dentition ( $p < 0.01$ ). Oberg et al. (1971) were also the first to comment on the localization of degenerative changes stating that “local arthrosis” is usually found in the lateral aspect of the joint affecting the disk and temporal component of the joint more often than the mandibular condyle. The authors theorized that TMJ OA “usually first involves the disk, which is perforated, and then the articular surface of the temporal component...The articular surface of the condyle is damaged last and usually not at all...” [5]. Finally, they commented that histologic changes of the condyle’s articulating surface seem to rarely develop into arthrosis.

The potential correlations presented by Bauer, Macalister, Blackwood, and Oberg et al. are still topics of modern TMJ research, specifically potential correlations between TMJ OA prevalence and/or severity with older age, sex, and dentition [5-9]. While researchers seem to agree that the prevalence and severity of degenerative changes increase with age until about the fifth decade of life (ages 40 to 50), there is some disagreement as to whether the correlations continue beyond the fifth decade [5, 6, 8, 10-13]. With regards to sex, some studies have indicated a statistically significant correlation between sex and the prevalence of TMJ OA [5, 7, 8, 14, 15], but others have found no such correlation [10, 12, 16].

Macalister (1954) and Oberg et al. (1971) reported that the prevalence and severity of TMJ OA correlate with edentulousness [5, 7], while Bauer (1941) observed increased degenerative changes with edentulousness or loss of lateral dentition [6]. However, more recent studies have found no correlation between TMJ OA and loss of dentition [12, 17, 18] than have reported a correlation [16]. Luder et al. (2002) reported a correlation between loss of occlusal support (lateral dentition), but not with overall tooth loss [10]. Interestingly, Magnusson et al. (2010) found that loss of occlusal support was correlated with TMJ degeneration in women at higher ages, but loss of occlusal support was not correlated with TMJ degeneration in men regardless of age (test subjects aged 18-100) [19].

The progression of degenerative changes over the three components of the TMJ (condyle, disc, and fossa) and the changes in severity of TMJ OA requires further research. Relevant to this work, some studies have found that TMJ OA results in significantly more degenerative changes over the condyle [8, 18-21], while others have found more degenerative changes over the temporal component [5, 22, 23]. Additionally, some studies have reported no significant difference in degenerative changes between the condyle and the temporal component [10, 11, 14]. Overall, there is a lack of agreement in the published literature.

Osteoarthritis (OA) is the most common degenerative joint disease which affects over 300 million people worldwide [24] and more than 32.5 million adults in the United States [25]. TMJDs have been shown to have a high comorbidity with general osteoarthritis [26, 27]. The knee joint is the joint most often affected by osteoarthritis [28]; and in a recent study, knee osteoarthritis patients were found to have a higher incidence of TMJD symptoms including limited ROM and sound or deviation with opening or closing [29]. However, while comparisons of TMJ OA have been made with OA of other joints such as the wrist [30], the sternoclavicular

and metatarsophalangeal [31], or the joints of the hand and fingers [30, 32-34]. To the best of our laboratory's knowledge, the work presented here, which was published in 2023, is the first to directly compare macroscopic degenerative changes in the TMJ to those in the knee joints of the same subjects [35].

Due to the conflicting results and conclusions reported by past studies and the recent scarcity of cadaver-based TMJ OA research, the objective of this study is to determine the prevalence and severity of OA on a macroscopic level in the TMJ and knee joints in a cadaver sample population. Severity findings will then be evaluated for correlations related to age, sex, and location within the TMJ (mandibular fossa vs. mandibular condyle). Lastly, similarities in OA findings between the TMJ and knee joint will be investigated.

## **Research Questions**

The objective of this thesis is to address the following research questions:

1. What is the prevalence of TMJ OA (fossa and condyle) in the sample population?
2. What is the average severity of TMJ OA (fossa and condyle) in the sample population?
3. Does the average severity of TMJ OA (fossa and condyle) increase with age?
4. Is there a difference in average severity of TMJ OA (fossa and condyle) between males and females?
5. Is there a difference in average severity of TMJ OA between the fossa and condyle?
6. Is there a difference in average severity of TMJ OA (fossa and condyle) and knee OA (femoral condyle)?

## Chapter 2: Previously Published Material

### Osteoarthritis Disease Severity in the Temporomandibular Joint and the Knee Joint: A Comparative Cadaveric Study

This chapter has been submitted to and published by *Cartilage* and is presented in the style of that Journal. The complete Citation is:

Immonen, J. A., Ciccotelli, J., Nguyen, L. M., Gilmer, L., Broadhead, L., Kitchen, M., Paul, C., & James, J. (2023). Osteoarthritis Disease Severity in the Temporomandibular Joint and the Knee Joint: A Comparative Cadaveric Study. *Cartilage*, *14*(4), 445–454.  
<https://doi.org/10.1177/19476035231189839>

#### Role of Authors:

JI was responsible for the overall project design. JI, JC, LN, LG, LB, MK, CP, and JJ were responsible for data generation and analysis. JI, JC, LN and JJ contributed to the writing and editing of this manuscript. All authors have read and agreed to the published version of the manuscript.

#### Abstract

**Objective.** The objective of this study was to determine the level of disease severity in a pilot cohort of temporomandibular joints (TMJs) and compare them to the pathology findings previously characterized in cadaveric knee joints. **Design.** Thirty-one intact TMJs from 17 cadaveric donors were harvested and arthritic lesioning seen in the knee joint was investigated on the condyle and the fossa of the TMJ. Prevalence of gross alterations was equated and disease severity was determined for sex- and age-based donor pools using a validated, OA disease severity scale (DSS). Knee joint DSS scores were also compared to the TMJ condyle and fossa DSS scores and a case study was carried out on a male donor that demonstrated severe OA in the both joints. **Results.** The mandibular fossa demonstrated an increase in disease severity compared to the mandibular condyle in a mixed sex donor pool ( $p=0.035$ ). It was discovered that the younger females demonstrated statistically more pathological condyles compared to the older



half of the female subgroup ( $p=0.02$ ). TMJ fossa and knee joints demonstrated comparable OA severity and similar signs of cartilage disease in a single donor highlighting the systemic nature of OA. Conclusions. This study demonstrates that gross signs of OA in the TMJs of cadavers are comparable to pathology found in the knee. The mandibular fossa appears to be the site of more profound disease, implying translational movements may be more likely to induce biomechanically abnormal movement, loading and OA.

**Keywords:** osteoarthritis, diagnosis, knee joint, temporomandibular joint, articular cartilage, tissue

## **Introduction**

Osteoarthritis (OA) is the most common degenerative joint disease that affects over 300 million people worldwide and more than 32.5 million adults in the United States (1, 2). OA is characterized by chronic degeneration of hard and soft tissues associated with synovial joints. OA was long believed to be exclusively related to cartilage “wear and tear” but the pathogenesis is now better understood to be multifactorial and related to altered inflammatory signaling and remodeling processes (3, 4). All or most structures of the synovial joint may be affected by these processes but the articular cartilage demonstrates some of the most pronounced signs of pathology including linear cracks, fibrillations, erosions, stellate fractures and gross degeneration to exposure and damage underlying cortical bone (5, 6). In principle, any synovial joint can be affected by OA pathogenesis to produce pain, joint stiffness, functional impairments and reduced quality of life (7).

The temporomandibular joint (TMJ) is a bilateral synovial joint between the condyle of the mandible and the mandibular fossa of the temporal bone. The joint space is composed of an upper and a lower synovial cavity that are separated by a fibrocartilaginous articular disc. The

joint is capable of sliding/translational movements in the looser upper joint compartment and rotational/hinge-like movements in the tighter lower compartment (8, 9). The TMJ is a vital structure to the health and vitality of all individuals and is of crucial importance in the practice of dentistry. Temporomandibular disorders (TMDs) are fairly common pathologies and are estimated to affect between 5-12% of Americans; in 2022 this may represent as many as 40 million people (10). A systematic review that assessed 2,741 articles on TMDs estimated that as many as 31% of adults or elderly patients have a form of these disorders (11). Symptoms of TMDs include joint pain, pain in the muscles of mastication, decreased range of mandibular motion, abnormal joint noises and other various functional deviations. TMDs encompass a variety of acute and chronic diseases and can be classified into three subgroups, muscular disorders, disc disorders and joint disorders (10). Plain film radiology and CT are often utilized in the clinic to assess patients for bony alterations of the TMJ; osteophytes are easily visualized. CBCT has been shown to be superior in visualizing the mandibular condyle and cortical erosions whereas MRI is the gold standard for evaluating soft tissue changes at the TMJ (9). OA in the TMJ is relatively under studied and the current body of evidence is profoundly reliant on radiology to draw conclusions. Research on pathogenesis of TMJ OA is in its very early stages and a cadaveric approach to study helps advance understanding of cartilage degeneration in a way that is unobtainable through imaging, even CBCT.

The objective of this study was to determine the level of disease severity in a pilot cohort of temporomandibular joints (TMJs). A validated scale for disease severity of OA in the knee joint was utilized to interpret pathology in the TMJs while statistically validating the scale's usage in the new joint. In the knee joint, it was demonstrated that there were no statistically significant differences in disease severity on the femoral condyles between the sexes but disease

severity did demonstrate significant increases with aging (Immonen 2020). Gross alterations to the cartilage of the TMJ were assessed for prevalence and specific location and frequency data was generated; disease severity was correlated to age and sex. This study also aims to help advance the knowledge of TMJ OA in the field of dentistry as dental considerations related OA are researched less regularly compared to OA and its effects on mobility, obesity and lower extremity joint pain. There are few osteoarthritis investigators that work in cadaveric models and examination of arthritic TMJs is an even rarer pursuit. This pilot body of work represents the development of a new specific aim within an osteoarthritis research program. This work intends to incorporate pathology examined and treated by dentistry and maxillofacial surgery to better interpret holistic osteoarthritis presentation and management.

## **Methodology**

### Cadaveric Dissection and Accrual

Thirty-one intact TMJs from 17 cadaveric donors were harvested from skull dissections. Donor sex, age at death and primary cause of death are provided in Table 1. Mandibles were disarticulated from the skull by transversely cutting the neck of the mandible and opening the lateral side of the TMJ capsule. The zygomatic arch and calvaria were removed using an autopsy saw. The dura and brain were then removed from the cranial cavity and two frontal plane cuts were created to the anterior and posterior aspect of the mandibular fossa of the temporal bone. The posterior cut was placed just anterior to the tragus and the anterior cut was aligned with the removal of the zygomatic arch. Frontal plane cuts were made to the depth of the foramen spinosum in the middle cranial fossa. Donors were acquired from the University of California Irvine Body Donation Program and the University of California San Diego Body Donation Program. This project (IRBNet ID 1681548-1) was reviewed by University of Nevada Las

Vegas' Institutional Review Board in Las Vegas, NV, and was determined to be research not involving human subjects.

Donor ID	Sex	Age	TMJ Condyle OA Rating	TMJ Fossa OA Rating	Femoral Condyle OA Rating
UCI 19-180 TMJ R	F	78	3	3	4
UCI 19-195 TMJ R	F	84	2	2	4
UCI 19-215 TMJ L	F	76	2	2	3
UCI 19-215 TMJ R	F	76	1	2	3
UCI 19-222 TMJ L	F	71	1	2	4
UCI 19-222 TMJ R	F	71	3	3	4
UCI 20-109 TMJ L	F	69	4	4	3
UCI 20-109 TMJ R	F	69	3	2	3
UCI 20-113 TMJ L	F	79	1	2	4
UCI 20-113 TMJ R	F	79	3	4	3
UCI 20-118 TMJ L	F	69	4	4	3
UCI 20-118 TMJ R	F	69	4	4	4
UCI 20-121 TMJ L	F	69	4	4	3
UCI 20-121 TMJ R	F	69	3	2	4
UCI 19-200 TMJ L	M	86	2	2	3
UCI 19-200 TMJ R	M	86	2	3	3
UCI 19-204 TMJ R	M	95	1	2	4
UCI 20-126 TMJ L	M	82	2	3	4
UCI 20-126 TMJ R	M	82	2	3	4
UCI 20-127 TMJ L	M	92	4	4	3
UCI 20-127 TMJ R	M	92	4	4	2
UCI 20-132 TMJ L	M	83	3	2	2
UCI 20-132 TMJ R	M	83	2	2	2
UCI 20-004 TMJ L	M	91	4	4	4
UCI 20-006 TMJ L	M	80	3	3	4
UCI 20-006 TMJ R	M	80	2	3	3
UCI 21-120 TMJ L	M	93	3	4	2
UCI 21-120 TMJ R	M	93	3	4	2

TMJ = temporomandibular joints; OA = osteoarthritis; UCI = University of California Irvine.

**Table 1.** Identifying number, sex, age of death, and primary cause of death for the 16 cadaveric donors composing the specimen pool

## TMJ Photography

The anatomy of the TMJ was photographed using a 12-megapixel iPhone 13 Pro camera. All photographs included a drafting ruler for calibration. The condyle of the TMJ was photographed from the anterior, medial, lateral and posterior views on two different backgrounds to allow for better interpretation of gross signs of OA. The disarticulated mandibular fossa was placed on the benchtop and photographed with calibration from above on two different backgrounds.

## Gross Signs of OA

Specific types of lesioning seen in arthritic knee joint cartilage were investigated on the condyle of the mandible and the mandibular fossa of the temporal bone using the Kovler et al. 2014 validated, OA disease severity scale described in the following section. This scale was validated in other synovial joints, most recently in the knee joint (12, 13). Superficial pitting, fraying or splitting would be indicative of Mild OA. Fibrillations are a specific type of focal, superficial damage that is a classical presentation of Mild OA. Fibrillations are early degenerative changes in osteoarthritis, marked by softening of the articular cartilage due to superficial proteoglycan losses and collagen disorganization, water retention and cleft formation between groups of cartilage cells (14-16). Investigators who have long been involved with this OA research program describe these pathologies as “fuzzy” in appearance. Extensive ulceration or cartilage loss would be indicative of Moderate OA. When a specimen demonstrates large areas of complete chondral degeneration accompanied by exposure or eburnation of bone it is indicative of Severe OA. Eburnation is a degenerative process of bone commonly found in patients with osteoarthritis or non-union of fractures. Altered inflammatory signaling seen with OA will cause bone thickening and reactive conversion of the sub-chondral bone to an ivory-like

sclerosis at the site of the cartilage erosion (17). Visible, gross alterations to the cartilage such as linear cracks or articular cartilage erosions could be signs of mild, moderate or severe OA depending on the depth of damage (6,14-16).

### Rating of Disease Severity

Cadaveric dissection and deep visual assessment of the intracapsular anatomy of the TMJ is not widely carried out in educational labs. Due to this lack of educational emphasis, cadaveric research involving the regional anatomy and gross signs of OA is even more rare. This considered, there were no known anatomical or clinical regional experts on cadaveric TMJ OA. A validated tool developed to describe knee joint OA disease severity was utilized in this assessment (12). This scale classes a synovial joint between Grade 0 OA, demonstrating no visible changes, to Grade 4 OA which represents severe OA. Specific gross surface features of the cartilage are listed as criteria to be classified as “No OA” (Grade 0), “Questionable OA” (Grade 1), “Mild OA” (Grade 2), “Moderate OA” (Grade 3) and “Severe OA” (Grade 4) and detailed in Table 2. Sample images of Grade 1-4 OA on the TMJ are demonstrated in Figure 1 and are further discussed in the results. Currently, there are no specimens in the donor pool classified as Grade 0 OA likely, based on the fact we have not had the opportunity to assess any donors below the age of 69-years old. The MANKIN or OARSI scales may be more familiar to some investigators but were not utilized in this assessment based on the absence of histological assessment completed.

Grade	Characterization	Surface Features
0	Normal Cartilage	No visible changes
1	Questionable if OA is Present	Slight unevenness, granularity of the surface, shallow furrows or streaking
2	Mild OA	Superficial fraying, superficial splitting, superficial pitting
3	Moderate OA	Extensive ulceration, cartilage loss
4	Severe OA	Large areas of complete degeneration, accompanied by exposure and eburnation of bone

**Table 2.** Scale modified from Kovler et al. (2004) to be implemented in the knee joint and the TMJ

Two blinded raters assessed the 31 TMJs for disease severity using the scale. A brief calibration session was carried out to clearly demonstrate examples of the surface feature irregularities seen with each grade of OA severity. This calibration session was carried out using knee joint images as to not use specimens included in the study at hand or bias the raters. Site of most profound disease (condyle or fossae) was noted for each TMJ specimen.

Additional anatomical information was collected for each TMJ specimen including condylar variation and state of articular disc degeneration. Condylar variation was based on the anatomical types discussed in Hegde 2013; the condyles were classed as Angled, Flat, Convex or Round on the frontal plane (9). Discs were classed to have mild, moderate or severe wear based on the presence of transparency, small holes or large erosions. Many discs did not demonstrate visible wear.

### Statistics

Statistical analyses were ran using SPSS statistics software. The Krippendorff's alpha ( $K\alpha$ ) test (18) was used to estimate the interrater reliability of two OA raters' condyles and

fossae disease severity scale (DSS) scores. Assessments were ran using SPSS v27 (IBM Corp); an Alpha of 1 to 0.8 represents strong interrater reliability. Condyle and fossae cartilage DSS ratings were compared using a two-sample t-test with equal variance. This test was also utilized to determine if there was a statistically significant difference in the DSS scores for the TMJ condyle and the fossae between the sexes and in the older compared to the younger subgroups.

#### Case Study: 91-year-old Male Demonstrating OA in Multiple Joints

Severe gross signs of osteoarthritis appeared to present comparably in the TMJ and knee joint of a single, 91-year-old male donor. This led investigators to thoroughly assess this specific donor's knee joints in addition to the TMJ. Severity of OA findings related to disease progression were evaluated in the right knee and the left TMJ. The left knee joint presented with a total joint replacement and the right TMJ was damaged in student dissection. The validated disease severity scale was used to assess the joints and significant signs of disease such as osteophytes, deep cartilaginous damages and fibrocartilage damages were noted.

#### Donor Assessment for Knee Joint OA

Of the 31 TMJs that were harvested from this donor pool, 28 had available knee joints for inclusion in this study. In a previous study, the disease severity scale at hand was utilized and validated on a larger pool of knee joint specimens that included this subgroup (12). DSS ratings for the 28 femoral condyle specimens were identified from this previous analysis where interrater reliability was demonstrated; these ratings were utilized in this novel comparison to the TMJ condyle and fossa DSS scores. Final statistical analysis involved comparing DSS scores for the TMJ condyle, TMJ fossa and femoral condyles of a single donor.



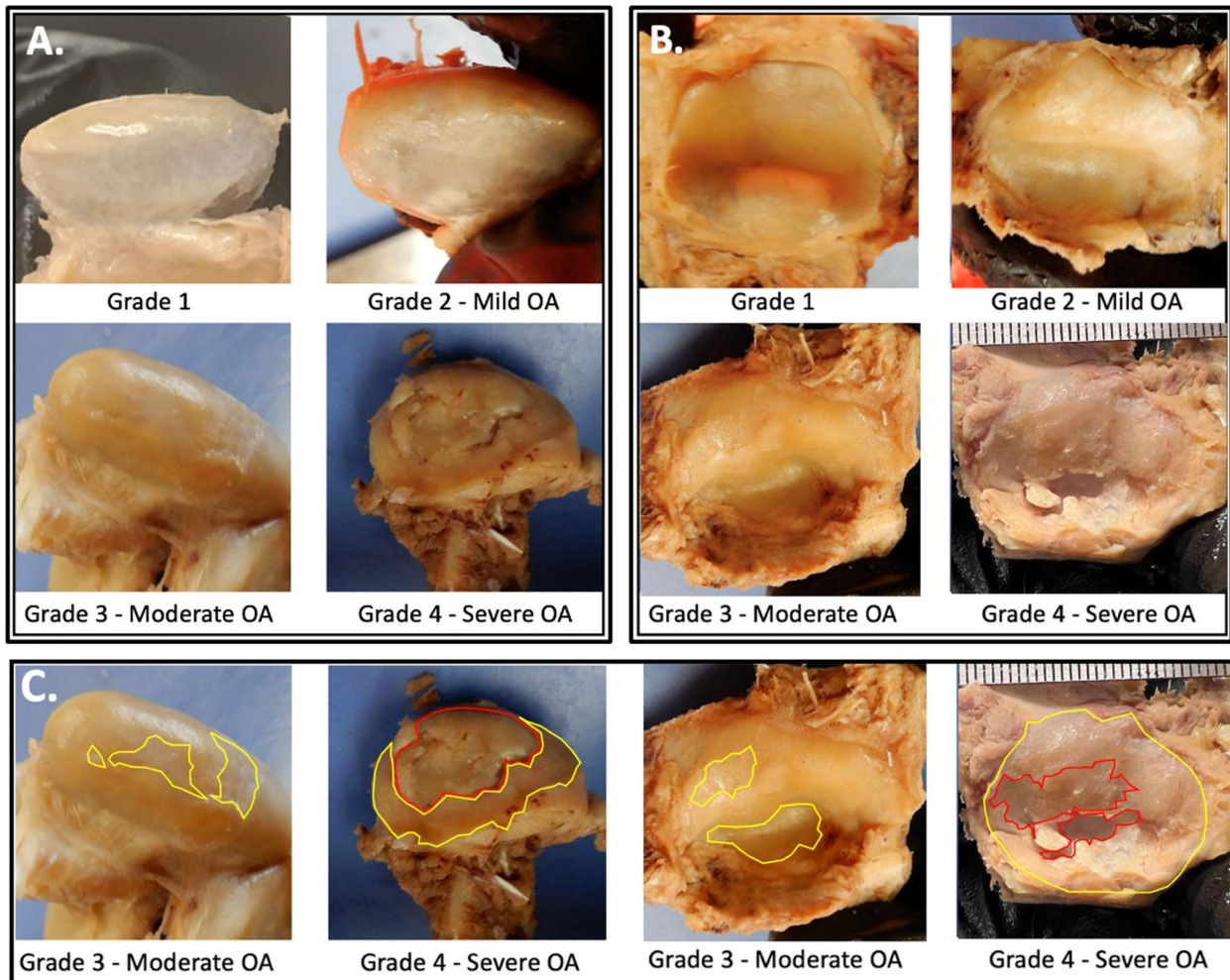
## Results

Superficial pitting and fibrillations were the most common form of degeneration in specimens with mild TMJ OA in this donor pool. Mild signs of OA often accompanied more pathological signs of OA on donors that were classed to have moderate or severe OA based on the disease severity scale. Donors with severe TMJ OA demonstrated extensive cartilage loss and cortical bone exposure. The mandibular fossa was more prone to demonstrate OA pitting (58%) and cartilage loss (46%) compared to the condyle (38%, 23%).

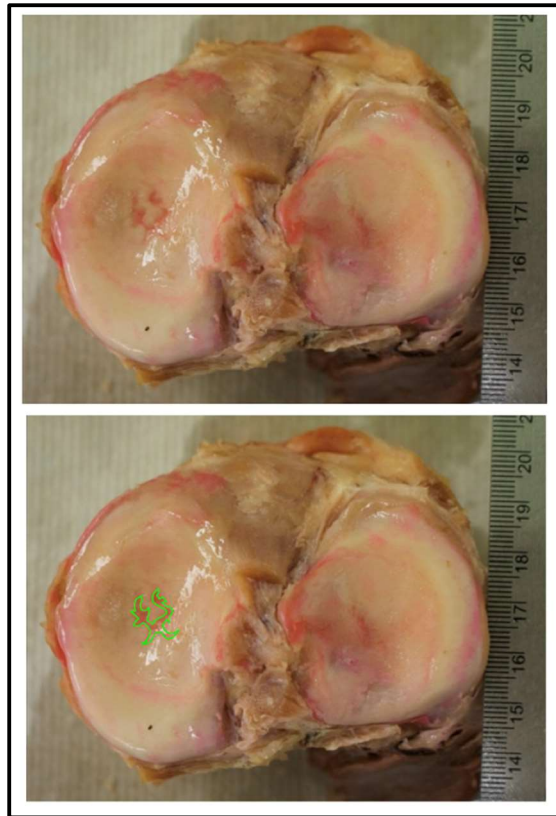
This study established that the validated scale for disease severity utilized in the hip, wrist and knee joint of previous studies is an appropriate tool to utilize in disease severity assessment of the TMJ. Superficial pitting, fibrillations, articular cartilage erosions and gross degeneration of the articular cartilage surfaces were all exhibited on a subset of TMJ specimens included in the study. Superficial pitting is a key element to be classed as Grade 2 OA based on this scale whereas cartilage erosion is a key element to be classed as Grade 3 or 4 (contingent on depth of erosion). Given these are requirements to be scored a Grade 2, 3 or 4 using this scale it was critical that investigators identified these gross signs of OA in the donor pool to justify the utilization of this tool. Both findings were regularly demonstrated on the mandibular fossa as well as on the mandibular condyle. Representative specimen images are included in Figure 1A-B to provide examples of these types of damages on the TMJ articular surfaces.

Figure 1C demonstrates moderate and severe TMJ condyles and fossae. Specimens with severe OA demonstrate multiple depths of damage with large surface areas of cortical bone exposure and/or cortical bone damage (red). Specimens with Moderate OA demonstrate substantial areas of cartilage erosion (yellow); depth of damage tends to be more uniform with Moderate OA with less damage to the underlying bone. Stellate fractures, a common finding in

the knee joint, were not demonstrated in this donor pool of TMJs (Figure 2). The validated scale does not specifically address stellate fractures as a specific requirement to be classed as a 0-4 Grade. Given these results, it was concluded that this scale for OA disease severity could be effectively used to class disease in arthritic TMJs.



**Figure 1.** This figure represents sample images for Grade 1-Grade 4 OA disease severity on the TMJ condyle (Figure 1A) and the TMJ articular fossa (Figure 1B). Grade 0 OA findings have yet to be dissected in this research program likely based on the youngest donor's age (69 years old). Figure 1C represents samples of denuded regions of cartilage on Moderate and Severe TMJ condyles and fossae. Specimens with Severe OA demonstrate multiple depths of damage (red and yellow traces). Specimens with Moderate OA indicate regions with cartilage erosions and lesser damages to the underlying cortical bone.



**Figure 2.** Sample image of a stellate fracture on the medial tibial plateau. Lower image is a duplicate of the above knee with the stellate fracture highlighted. Stellate fractures are often visible on specimens demonstrating moderate or severe OA. Pink coloration to the stellate fracture is an artifact of the embalming process.

The mandibular fossa demonstrated a statistically significant increase in disease severity compared to the mandibular condyle in the mixed sex donor pool ( $p=0.035$ ). The condyle scored an average score of  $2.68 \pm 0.96$  on the OA disease severity scale (DSS) and the mandibular fossa scored an average of  $2.90 \pm 0.76$  on the DSS. There was no statistically significant difference in the disease severity scoring of condyle or fossa specimens based on sex. The average DSS rating for the subgroup of female condyles was  $2.73 \pm 1.21$  and  $2.63 \pm 0.78$  for the male condyles. The average DSS rating for the subgroup of female fossae was  $2.87 \pm 0.84$  and  $2.94 \pm 0.73$  for the

male fossae. The K $\alpha$  results show high interrater reliability between the two raters of the condyles ( $\alpha = .9353$ ) and of the fossae ( $\alpha = .9816$ ). Based on the scoring provided by the most experienced rater it was determined that the condyle and fossa of a single donor demonstrated equivalent disease severity in 58% (18/31 TMJs) of the donor pool. The fossa was the most degenerated in 29% (9/31) of specimens. The condyle was the most degenerated in 13% (4/31 TMJs) of specimens. Most importantly with respects to the biomechanical discussion to come, the fossa was most degenerated or equivalently degenerated as the condyle in (27/31) 87% of the donor pool at hand.

When the specimens were broken up into age groups 75 years old and below (youngest), 76-80 years old (middle) and 80 years old and above (oldest) there was no statistically significant difference in the disease severity scoring of specimens based on age for the condyle or the fossa (DSS score for condyles: youngest  $3.25 \pm 1.07$ , middle  $2.3 \pm 0.68$  and oldest  $2.62 \pm 0.92$ . DSS score for fossae: youngest  $3.13 \pm 0.98$ , middle  $2.6 \pm 0.49$  and oldest  $3.00 \pm 0.83$ ). The sample was also divided in half by age, representing age groups of 69-79 years old and 80-95 years old. There was also no statistically significant difference in the disease severity scoring of specimen condyles or fossae based on this age breakdown ((DSS score for condyles: youngest  $2.75 \pm 1.13$  and oldest  $2.6 \pm 0.83$ . DSS score for fossae: youngest  $2.81 \pm 0.83$  and oldest  $3.00 \pm 0.71$ ).

The donor pool was also divided by sex and split into age subgroups for statistical analysis (male=16; younger=8, older=8 / female=15; younger=8, older=7). The subgroups were compared for disease severity on the condyle and the fossa. There was no statistically significant difference in disease severity on the TMJ fossa between the younger (69-71 years old; N=8) and older (76-84 years old; N=7) and females. There was a statistically significant difference in the disease severity on the TMJ fossa between the younger (78-83 years old; N=8) and older (86-95

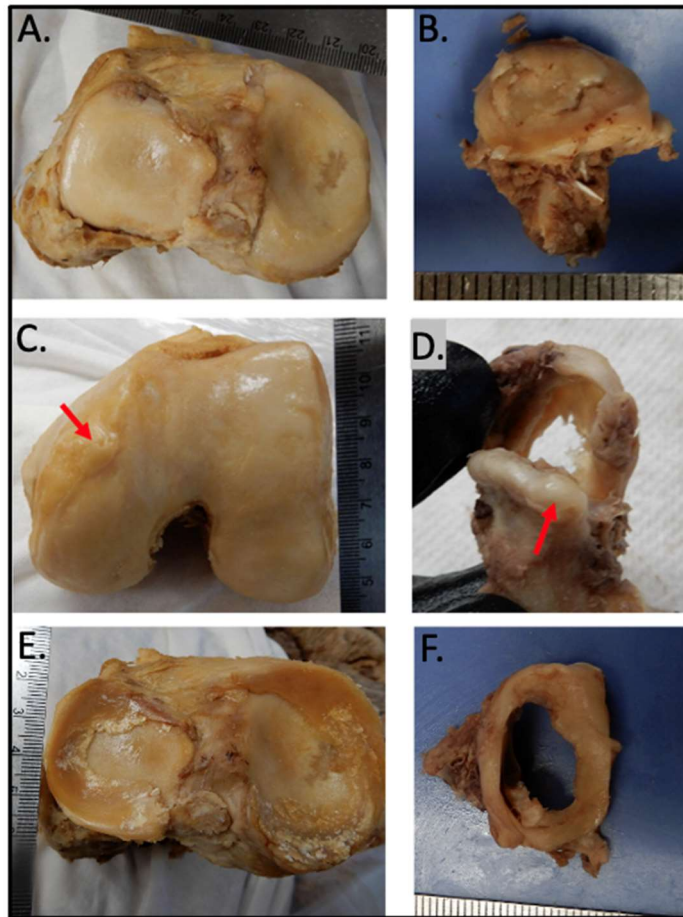
years old; N=8) males; older male TMJ fossae demonstrated more severe OA findings (DSS score for younger males  $2.5 \pm 0.29$ , DSS score for older males  $3.38 \pm 0.84$ ; \* $p=0.02$ ). When statistically comparing the younger and older female condyles for disease severity it was discovered that the younger females demonstrated more pathological condyles compared to the older half of the female subgroup (DSS score for younger females  $3.25 \pm 1.07$ , DSS score for older females  $2.14 \pm 0.81$ ; \* $p=0.02$ ). There was no statistically significant difference in disease severity on the TMJ condyle between the younger and older males.

The pathology of the articular disc was not statistically assessed with the validated scale for disease severity but obviously provided investigators with information on a specimen's disease progression. Only 30 of the 31 total specimens had appropriate photography of the articular disc for this assessment; 17 of the 30 specimens (57%) of the articular discs demonstrated visible wear. Of those 17 specimens, 35% (6/17) demonstrated severe degeneration, 18% (3/17) demonstrated moderate degeneration and 47% (8/17) demonstrated mild degeneration. It was hypothesized that condyle variation may affect the degree of degeneration present on a specimen.

This study demonstrates that gross signs of OA in the TMJs of cadavers are comparable to pathology found in the knee based on qualitative disease observations in addition to the previously mentioned nonparametric statistics. Similar articular cartilage and fibrocartilage disease findings presented on the TMJ and knee joint of a 91-years old donor highlighting the systemic nature of OA. Osteophyte development and fibrocartilage damages occurred on both of the joints in the same donor. The right knee of a 91-year-old male donor demonstrated osteophyte growth on the anteromedial femoral condyle and extensive cartilage loss of the femoral condyles and the tibial plateau. The left knee joint was a total replacement so it can be

inferred the OA disease progression was severe. The contralateral (left) TMJ was harvested from the same donor and also demonstrated severe cartilage erosion and linear cracking of the articular cartilage. A sizeable osteophyte was found on the superolateral aspect of the mandibular condyle. The menisci and the articular discs are fibrocartilaginous structures of the knee and TMJ, respectively. These structures appeared to wear in a similar fashion in the donor. The articular disc was completely worn through centrally and a fibrocartilaginous ring was the only persisting remnant of the articular disc (Figure 3).

There appears to be a correlation in the degenerative processes seen on the femoral condyles and the mandibular fossa. The mandibular condyle demonstrated significantly less severity in OA presentation compared to the femoral condyles (\* $p=0.04$ ) in the mixed sex donor pool (N=28) whereas the fossa was comparably pathological to the knee (Average DSS score for mixed sex TMJ condyles  $2.68 \pm 1.00$ , DSS score for TMJ fossae  $2.96 \pm 0.87$ , DSS score for femoral condyles  $3.25 \pm 0.74$ ). When OA signs were assessed in same sex donor groups (female N=14, male N=14) the mandibular fossa and the knee joint were consistently comparable whereas the mandibular condyle was statistically less pathological compared to femoral condyles from the same donor (\* $p=0.05$  for male and female comparisons).



**Figure 3.** This figure represents similar gross findings of OA in the knee joint and the TMJ on a single 91-year-old donor. A and B represent articular cartilage defects that were similar on the knee joint and the mandibular condyle. Linear cracks and large cartilage erosions were present. C and D represent similar osteophyte growth at the margins of the articular cartilage surfaces. E and F represent equivalent damage and degeneration to fibrocartilage structures, specifically the menisci of the knee and the articular disc of the TMJ.

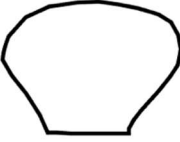


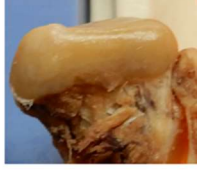
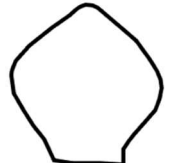



## Discussion

The literature pool related to the study of osteoarthritis in the TMJ is limited compared to other synovial joints in the body that regularly experience the inflammatory condition. An even fewer number of research teams are investigating TMDs in a cadaveric model making these findings quite novel. Prior to analysis, there were two potential hypotheses related to disease severity in the TMJs compared to disease severity that has previously been assessed on the femoral condyles (12). One plausible hypothesis was that the femoral condyles may demonstrate greater disease severity compared to TMJs of similar age due to the fact they are weight-bearing joints. The TMJ is not a weight-bearing joint along the line of gravity but Zhao and Ye (1994) demonstrated that the maximum male bite force of the first molar was 120.66 kg or approximately 266 pounds (19). These findings make hypothesizing greater or equivalent disease severity in the TMJs compared to the knee joints also reasonable. Human bite force data highlights how understandable it is to see such a large percentage of the population experience TMDs and gross alterations to the TMJ articular cartilage regardless of its stronger, fibrocartilage phenotype. Knee joints from donors that were 80 years old and above showed the highest disease severity scores whereas this study showed that the greatest average disease severity for the TMJ condyles and fossae were seen in the youngest donors (12). This comparison emphasizes the complexity of TMDs and the plethora of physical and mental influences that may lead to degeneration of TMJ anatomy.

Similar to findings in knee joint OA cadaveric donors, superficial pitting and fibrillations were the most common form of degeneration associated with mild disease and accompanied more exacerbated findings such as extensive craters and bone exposure in donors with moderate and severe disease. Unlike the knee joint, linear cracks were quite uncommon on TMJ condyles



and fossae, presenting on only a single severely arthritic TMJ condyle. In this donor pool, there were no discernible stellate fractures, a manifestation of OA commonly seen as a central deformity of the medial or lateral compartment of the tibial plateau. As far as disease presentation on the articular disc, the findings in this donor pool were very polarized. Discs were most regularly classed as mildly or severely degenerated indicating that once the pathogenesis and formation of a perforation begins it progresses quickly. The least prevalent anatomical variants of the TMJ condyle, the angled and rounded morphologies, all accompanied joints expressing moderate and severe disease with full-thickness holes in the articular disc. This may relate to classical explanations on evolution and natural selection; a disadvantageous feature may be bred out of a population to produce a stronger future generation. Sample images of the variations of mandibular condyles are included in Figure 4 and are listed from most common to least common based on the current literature (9). The greater severity of pathology on the condyles of the Angled and Rounded variant representative images compared to the Convex and Flat variants is apparent.

Variant	Schematic	Representative Specimen
Convex		
Flat		
Angled		
Round		

**Figure 4.** Figure demonstrates the variations of the mandibular condyle drawn in schematic and by representative photographs from the donor pool. Variants are listed from least common to most common in a recent assessment population (Hegde 2013). More severe signs of OA on the Angled and Rounded condyles are apparent in the representative photographs.

Assessing disease severity in the TMJs was more challenging compared to the assessment of the femoral condyles for several reasons. It is difficult to identify investigators with expertise in arthritic cadaver joints, especially TMJs. Many investigators that implement cadaveric dissection in their research are affiliated with biomedical sciences education in medical programs and these programs typically do not have a strong dissection emphasis on structure pertinent to dentistry such as the TMJ. Preparing specimen raters that have dissected TMJs, let alone had assessed TMJs for signs of disease, was regionally impossible so a calibration protocol for

interpreting gross signs of cadaveric osteoarthritis was developed. Other limitations in this study warrant mentioning such as the minor degree of shadowing generated with the selected camera. This shadowing was offset but the substantially better quality of defect visualization seen with the iPhone 13 compared to a single-lens digital camera. All and all, the results of this assessment are to be considered with the context of a pilot population that heavily draws on case report data and future studies with a greater population size should be carried out.

This calibration protocol utilized arthritic knee joint specimen photographs from previous studies to highlight sample images of mild, moderate and severe osteoarthritis, Grades 2-4 on the disease severity scale. The calibration protocol also provided examples of superficial pitting and fraying, fibrillations and extensive cartilage loss. Moderate disease severity was described to demonstrate extensive cartilage loss on less than half of the specimen condyle or fossa. Severe OA was described to demonstrate extensive cartilage loss over more than half of the specimen. Often, specimens with severe OA demonstrated complete cortical bone exposure with potential damages to the underlying bone.

Once specimens were scored it was determined that there was strong interrater reliability using this assessment tool previously validated in the knee, hip and wrist joints. Separate disease severity scoring for a single TMJ specimen's fossa and condyle allowed investigators to determine that the mandibular fossa appears to regularly be the site of more profound disease or equivalently profound disease as the condyle. This suggests the upper joint compartment laxity of the TMJ and the translational movements occurring there may be more likely to induce biomechanically abnormal movement, loading and OA compared to the hinging movements generated in the lower joint compartment.

There was no statistically significant difference in the disease severity scoring of the condyles or the fossae within this donor pool based on sex or age. The only comparisons that generated statistical significance were when the younger half of the female or male subgroups was compared to the older half of the female or male subgroups. Age groups were determined by splitting the donors in half; for the female subgroup, the younger specimens represented donors 69-71 years old and the older specimens represented donors 76-84 years old. Interestingly, younger females demonstrated more profound disease than older females ( $p = 0.02$ ). Aging has a chief role in onset of disease findings and severity of degeneration in the knee joint (12, 17, 20-22) but the aging process is seemingly a lesser factor compared to other influences that propel TMJ OA pathogenesis in women. For example, American women who experience a younger age of death may often be less healthy with accompanying comorbidities. Four out of the 8 female donors included in this donor pool had documented causes of death, such as atherosclerotic vascular disease and hypertensive heart failure, that could theoretically be prevented or reduced based on lifestyle choices. Age may be a lesser factor in the development of TMJ OA if systemically the patient is unhealthy. Additionally, social psychology and mental health research emphasize that a greater mental load is often put on women in heterosexual relationships, especially during child-bearing years, and substantial stress may be present from this potential unequal distribution of effort (23, 24). TMDs are known to have a strong correlation with mental health diseases, anxiety disorders and stress and as many as 75% of TMD patients have a significant psychological abnormality (25).

These findings have importance in the dental clinic. It is reasonable to anticipate that the greater mobility and translational movements in the upper joint compartment would manifest more pathology. Normal chewing, and to a greater degree in cases of bruxism, significant lateral

translational movements at the TMJ occur. In patients with bruxism, these lateral excursions can become exceptionally pronounced and would predominantly or solely alter the integrity of the upper joint compartment. It has been documented that when patients chewed increasingly harder foods, the masticatory width or lateral movement of chewing increased to increase the bite force (26). From a dentistry perspective, one of the first recommendations given to TMD patients is to begin a soft food diet for 2-4 weeks to reduce chewing and allow for healing in the joint space. A bite splint is also a common approach to treating TMD patients because it protects the teeth during nighttime grinding and props the bite slightly open. This encourages healing in the joint space as the mandibular condyle is not capable of pressing on the articular disc and mandibular fossa as forcefully. As minor mouth opening is predominantly hinge movement and translational movements occur secondarily to allow for greater mouth opening, patients with severe TMD can experience a limited ability to depress the mandible. These patients face difficulty maintaining weight and adequate nutrition due to limited mouth opening, chewing motion, and generation of substantial bite force (27).

The case study on the 91-years old male donor is a perfect example of the systemic nature of osteoarthritis. Similar articular cartilage disease findings such as osteophytes, extensive erosions and linear cracking presented on the TMJ and knee joint whereas there were also similar damages to the fibrocartilage structures. The menisci and the articular disc both demonstrated notable wear, especially at the sites of greatest intracapsular contact. Interestingly, the articular surfaces in the knee joint are lined with hyaline cartilage whereas the TMJ articular surfaces are lined with stronger fibrocartilage. Similar findings appear in both cartilage types implying the cartilage breed isn't a limiting factor to disease progression. It could be questioned as to whether cadaveric signs of pathology in the TMJ are as assured to be osteoarthritis as they are in the knee

joint. This cadaveric case report suggests dysregulated inflammatory signaling is a likely culprit for the gross alterations to the joint given the multiple pathology correlations to the patient's knee joint and the high prevalence of osteoarthritis in the United States. From a patient care perspective, it is important to consider these common OA manifestations based on systemic inflammatory and metabolic alterations when educating patients on their joint dysfunction and pain, highlighting other joints are likely to become affected without lifestyle alterations.

### **Acknowledgements**

The authors wish to thank individuals who donate their bodies and tissues for the advancement of education and research.

## References

1. Safiri, S., Kolahi, A. A., Smith, E., Hill, C., Bettampadi, D., Mansournia, M. A., ... & Cross, M. (2020). Global, regional and national burden of osteoarthritis 1990-2017: a systematic analysis of the Global Burden of Disease Study 2017. *Annals of the rheumatic diseases*, 79(6), 819-828.
2. Centers for Disease Control and Prevention; Arthritis Foundation. A national public health agenda for osteoarthritis. Available from: <https://www.cdc.gov/arthritis/docs/oa-agenda.pdf>
3. Loeser RF, Goldring SR, Scanzello CR, Goldring MB. Osteoarthritis: a disease of the joint as an organ. *Arthritis Rheum*. 2012;64(6):1697-707. doi:10.1002/art.34453
4. Xia, B., Chen, D., Zhang, J., Hu, S., Jin, H., & Tong, P. (2014). Osteoarthritis pathogenesis: a review of molecular mechanisms. *Calcified tissue international*, 95(6), 495-505.
5. Immonen, J., Siefring, C., & Sanders, L. (2019). Osteoarthritis of the anterior cruciate ligament and medial tibial plateau: a cadaveric study. *Cartilage*, 10(1), 11-18.
6. Bauer M, Jackson RW. Chondral lesions of the femoral condyles: a system of arthroscopic classification. *Arthroscopy*. 1988;4(2):97-102.
7. Whittaker, J. L., Runhaar, J., Bierma-Zeinstra, S., & Roos, E. M. (2021). A lifespan approach to osteoarthritis prevention. *Osteoarthritis and Cartilage*, 29(12), 1638-1653.
8. Standring S. *Gray's anatomy: the anatomical basis of clinical practice*. 41st ed. New York, NY: Elsevier; 2015. p. 1349-411.
9. Hegde, S., Praveen, B. N., & Shetty, S. R. (2013). Morphological and radiological variations of mandibular condyles in health and diseases: a systematic review. *Dentistry*, 3(1), 154.

10. Yadav, S., Yang, Y., Dutra, E. H., Robinson, J. L., & Wadhwa, S. (2018). Temporomandibular joint disorders in older adults. *Journal of the American Geriatrics Society*, 66(6), 1213-1217.
11. Valesan, L. F., Da-Cas, C. D., Réus, J. C., Denardin, A. C. S., Garanhani, R. R., Bonotto, D., ... & de Souza, B. D. M. (2021). Prevalence of temporomandibular joint disorders: a systematic review and meta-analysis. *Clinical Oral Investigations*, 25(2), 441-453.
12. Immonen, J., Stevens, K., Albin, A., Chaus, D., Gilmer, L., & Zdilla, M. (2021). Assessment of the Degree of Osteoarthritis in Aging Male and Female Femoral Condyles: A Cadaveric Study. *Cartilage*, 13(1\_suppl), 1684S-1695S.
13. Kovler M, Lundon K, McKee N, Agur A. The human first carpometacarpal joint: osteoarthritic degeneration and 3-dimensional modeling. *J Hand Ther.* 2004;17(4):393-400.
14. Arokoski, J. P. A., Jurvelin, J. S., Väätäinen, U., & Helminen, H. J. (2000). Normal and pathological adaptations of articular cartilage to joint loading. *Scandinavian Journal of Medicine & Science in Sports: Review article*, 10(4), 186-198.
15. Saarakkala, S., Julkunen, P., Kiviranta, P., Mäkitalo, J., Jurvelin, J. S., & Korhonen, R. K. (2010). Depth-wise progression of osteoarthritis in human articular cartilage: investigation of composition, structure and biomechanics. *Osteoarthritis and Cartilage*, 18(1), 73-81.
16. Mononen, M. E., Mikkola, M. T., Julkunen, P., Ojala, R., Nieminen, M. T., Jurvelin, J. S., & Korhonen, R. K. (2012). Effect of superficial collagen patterns and fibrillation of femoral articular cartilage on knee joint mechanics—A 3D finite element analysis. *Journal of biomechanics*, 45(3), 579-587.



17. Loeser, R. F. (2017). The role of aging in the development of osteoarthritis. *Transactions of the American Clinical and Climatological Association*, 128, 44.
18. Hayes, A. F., & Krippendorff, K. (2007). Answering the call for a standard reliability measure for coding data. *Communication Methods and Measures* 1(1), 77-89.
19. Zhao Y, Ye D. [Measurement of biting force of normal teeth at different ages]. *Hua Xi Yi Ke Da Xue Xue Bao*. 1994 Dec;25(4):414-7. Chinese. PMID: 7744385.
20. Hasegawa, A., Otsuki, S., Pauli, C., Miyaki, S., Patil, S., Steklov, N., ... & Lotz, M. K. (2012). Anterior cruciate ligament changes in the human knee joint in aging and osteoarthritis. *Arthritis & Rheumatism*, 64(3), 696-704.
21. Pauli, C., Grogan, S. P., Patil, S., Otsuki, S., Hasegawa, A., Koziol, J., ... & D'Lima, D. D. (2011). Macroscopic and histopathologic analysis of human knee menisci in aging and osteoarthritis. *Osteoarthritis and cartilage*, 19(9), 1132-1141.
22. Sacitharan, P. K. (2019). Ageing and osteoarthritis. *Biochemistry and cell biology of ageing: part II clinical science*, 123-159.
23. Dean, L., Churchill, B., & Ruppner, L. (2022). The mental load: building a deeper theoretical understanding of how cognitive and emotional labor over load women and mothers. *Community, Work & Family*, 25(1), 13-29.
24. Garcia-Alonso, J., Krentz, M., Lovich, D., Quickenden, S., & Taplett, F. B. (2019). Lightening the mental load that holds women back. *Boston Consulting Group*, 1-6.
25. Buescher, J. J. (2007). Temporomandibular joint disorders. *American family physician*, 76(10), 1477-1482.
26. Komino, M., & Shiga, H. (2017). Changes in mandibular movement during chewing of different hardness foods. *Odontology*, 105(4), 418-425.

27. Temporomandibular Joint Association Ltd. (TMJA) Nutrition Guide. TMD Nutrition and You. Available from: [http://tmj.org/wp-content/uploads/2020/08/TMJ\\_nutrition\\_Guide.pdf](http://tmj.org/wp-content/uploads/2020/08/TMJ_nutrition_Guide.pdf)

## Chapter 3: Discussion

Most published studies that graded the severity of TMJ OA in post-mortem specimens used variations of a four-staged system as exemplified in Table 3 [5, 10, 14]. However, in this study, a five-staged system was used (Table 3) as it is difficult to differentiate remodeling vs. the initiation of degeneration when the changes to the articular surface are minor in scale [8, 36]. The five-staged system was previously used by Kovler et al. (2004) as an adaptation of the scale established by Byers et al. in 1970 [37, 38]. Use of this general OA scale also allows for future work comparing findings in the TMJ to published studies of degenerative disease in the knee and wrist joints [37, 39].

Akerman et al. 1984 [14]		Kovler et al. 2004 [37]; Immonen et al. 2021 and 2023 [35, 39, 40]		
Grade	Description	Grade	Characterization	Description
0	No changes of the type described below	0	Normal cartilage	No visible changes
1	Superficial flaking or fraying	1	Questionable if OA present	Slight unevenness, granularity of the surface, shallow furrows or streaking
2	Local reduction of soft tissue layer	2	Mild OA	Superficial fraying, superficial splitting, superficial pitting
3	Total loss of soft tissue with bone exposed	3	Moderate OA	Extensive ulceration, cartilage loss
		4	Severe OA	Large areas of complete degeneration, accompanied by exposure and eburnation of bone

**Table 3.** Comparison of grading scales used for evaluating levels of joint degeneration in published studies

Previous studies have reported prevalences of TMJ OA in older adults from as low as 10% to as high as 84% (see Table 4). In this study, all 31 TMJs from 17 donors were found to have notable degenerative changes over the mandibular fossa. Only 4 of the 31 mandibular condyles were rated as having questionable degenerative changes, while the remaining 27 condyles showed definitive degenerative changes rated as at least Grade 2 (Mild) OA.

Reference	Number of TMJs	Male TMJs: Female TMJs	Age Range of Subjects	Prevalence of OA
Akerman et al. 1984	44	26:18	60 to 86 male, 67 to 88 female	84%
Axelsson et al. 1987	84	44:40	41 to 92, mean 73	38%
Bean et al. 1977	20	14:6	58-90 male, 44-84 female	50%
Blackwood 1963	400		over 40	40%
De Bont et al. 1986	22		54 to 92	68%
Grunert et al. 2000	44	16:28	58 to 95	10%
Honda et al. 2001	61	30:31	52-93 male, 44-96 female	38%
Oberg et al. 1971	41	27:14	60 to 93	24%
Pereira et al. 1994 [23]	32		55 to 78	50%
Rohlin et al. 1985	55	27:28	40 to 99	29%
Toure et al. 2005	70	35:35	76 to 106, mean 91.8	68%
Westesson and Rohlin 1984	115	61:54	60 to 99	42%
Widmalm et al. 1992	27		56 to 82, mean 72	33%
Widmalm et al. 1994	248	154:94	33 to 94 for male, 43 to 92 for female	19.2% for 65 to 79, 34.7% for 80 years or above

**Table 4.** Autopsy-based studies reporting prevalence of TMJ OA in older adults

Disease severity was statistically evaluated for possible correlation with increasing age or subject gender and no statistically significant relationship was found in either case. Blackwood (1963), Bauer (1941), and Ishibashi et al. (1995) all found that TMJ degenerative changes increase in severity past the sixth decade of life (50's) [6, 8, 13]. In contrast, Luder (2002) found that degeneration seems to “attain a maximum at around 55-60 years and decline at still higher ages” [10]. Luder hypothesized that this may be because TMJ degeneration progresses nonlinearly and, in later stages, may come to a standstill.

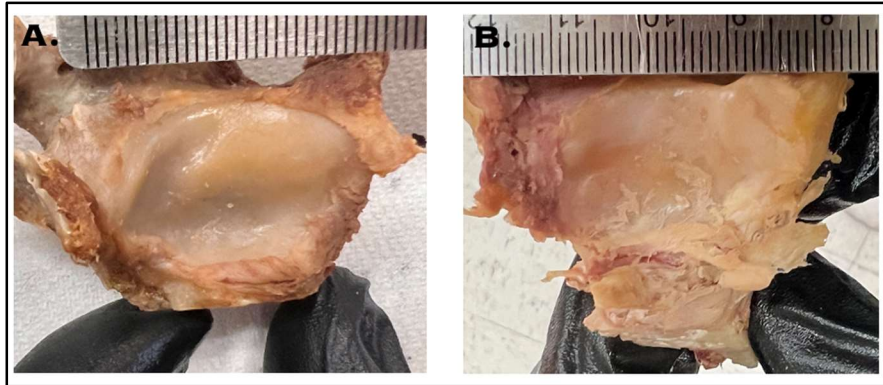
In this study, older females (76-84 years old) were found to have less severe mandibular condyle degeneration than younger females (69-71 years old). Meanwhile, older men (86-95 years old) were found to have more pathological fossae than the younger men (aged 78-83 years). While the first finding supports Luder's hypothesis of non-linear TMJ OA progression, the second finding conflicts with the hypothesis. Further investigation and data collection is needed to confirm correlations between OA severity and age within each gender.

The lack of correlation between disease severity and subject gender in this study is in agreement with some research [10, 12, 16] and in contrast with other research [5, 7, 8, 14, 15]. Most studies that have found a correlation between disease severity and subject gender have reported more severe degeneration in women [5, 7, 8, 14], but one study reported more severe TMJ degeneration in men [15].

In this study, the mandibular fossa was more degenerated or equivalently degenerated to the condyle in 87% of the TMJs examined. As mentioned in the introduction, this is similar to the findings of some previous studies [5, 22, 23] and in opposition with other studies which reported the condyle to be more affected by degeneration [8, 18, 19, 20, 21]. Another pool of

studies showed no significant difference in degeneration between the fossa and condyle [10, 11, 14].

While the quantitative data will be presented in a later publication [41], it is of note that the majority of degenerative changes observed in this study were found in the lateral aspect of the TMJ and joint components. An example of this preferential lateralization of degeneration in contrast to a more equivalent degeneration pattern can be seen below in Figure 5. Bean et al. (1977), Oberg et al. (1971), Nannmark et al. (1990), Pereira et al. (1994, both publications), Akerman et al. (1984), and Westesson and Rohlin (1984) all similarly noted that OA predominantly affected the lateral TMJ [5, 11, 14, 23, 42-44]. Hansson and Oberg reassessed the same 115 TMJs from Oberg et al. (1971) in a 1977 article and hypothesized that the lateral localization of degeneration is due to the anatomy and biomechanics of the TMJ in that the condyle is located lateral to the temporal component of the joint and the lateral pole of the condyle lies superior to the medial pole of the condyle [45]. Additionally, they stated, lateral movements of the condyle occur during both mastication and bruxism which stress the lateral aspect of the joint.



**Figure 5.** Images from Immonen et al. 2024 [41] demonstrate example mandibular fossae with preferential degeneration on the lateral side of the articular eminence (A) or equivalent wear across the entire articular eminence (B). Image A represents a right mandibular fossa and image B represents a left mandibular fossa.

Other sources tend to agree with Hansson and Oberg (1977) with regards to a biomechanical cause of lateral-sided degeneration. Gray’s Anatomy states that “[h]umans use lateral movement of the lower jaw to create a shear force that enhances the effectiveness of the power stroke of mastication” [1]. Bruxism is also associated with lateral movements of the jaw, but with significantly increased bite forces [46, p. 112]. In finite element analyses of the TMJ, both Perez del Palomar and Doblare (2006) and Sagl et al. (2022) found that lateral movements of the jaw generated the highest loads on the lateral portions of the joint, especially the lateral aspect of the fibrocartilage disc [47, 48].

Among the 28 subjects for which both TMJs and knee joints were evaluated, OA severity of the femoral condyles was found to be statistically comparable to that of the mandibular fossa. When subjects were divided into two groups according to gender, the mandibular condyle was statistically less degenerated than the femoral condyles. Because this study is the first to directly compare OA severity in the TMJs and knee joints of the same subjects, no previous studies are available for comparison. However, prior studies which tested for a correlation between

degenerative changes in the hand and fingers to the TMJ have reported conflicting results [30, 32, 33]. Kopp et al. (1976) found a weak correlation between degenerative changes in the metatarsophalangeal joints and the TMJs in the same subjects, but no significant correlation between degenerative changes in the sternoclavicular joints and TMJs [31]. It is hypothesized that the correlations between degeneration in the TMJs and the knees or metatarsophalangeal joints, but the lack of correlation between degeneration in the TMJs and hand or finger joints may be due to the load-bearing function of the temporomandibular joint, knee joint, and metatarsophalangeal joints in contrast to the joints of the hand and fingers. While the TMJ is not classically considered a weight-bearing joint, the typical forces applied to the teeth during normal functions are estimated to be 58.7 lbs while chewing and 66.5 lbs while swallowing [46, p. 112]. Zhao and Ye demonstrated the maximum male bite force at the first molar to be 120.66 kg or approximately 266 pounds [49].



## Chapter 4: Conclusions

### Answers to Research Questions

1. What is the prevalence of TMJ OA (fossa and condyle) in the sample population?

The prevalence of TMJ OA in the sample population was 87-100% in the condyles and 100% in the fossae.

2. What is the average severity of TMJ OA (fossa and condyle) in the sample population?

On a scale from 0-4, the average severity scores for the fossae and condyle were  $2.90 \pm 0.76$  and  $2.68 \pm 0.96$ , respectively, corresponding with mild to moderate OA.

3. Does the average severity of TMJ OA (fossa and condyle) increase with age?

Within the sample population, the severity does not increase with age.

4. Is there a difference in average severity of TMJ OA (fossa and condyle) between males and females?

Within the elderly sample population studied, there is no difference in average severities between males and females.

5. Is there a difference in average severity of TMJ OA between the fossa and condyle?

Yes, the TMJ fossa is generally more affected.

6. Is there a difference in average severity of TMJ OA (fossa and condyle) and knee OA (femoral condyle)?

Yes, the TMJ fossa and femoral condyle are comparably degenerated, while the TMJ condyle is less degenerated.

## **Limitations**

One limitation of this study is the relatively small sample size; this is due to cadaver availability as a single institution research program. The cadaver lab only houses and utilizes 8 donors (16 TMJs) per year. Donors were acquired through the University of California Irvine Body Donation Program and the University of California San Diego Body Donation Program. This research project is intended to be continued by future investigators to increase the sample size of joints examined.

Another limitation of this study is the lack of microscopic or histological evaluation to correlate with the macroscopic evaluation of specimens. Blackwood (1969), De Bont et al. (1986), and Flygare et al. (1992) all examined TMJ specimens both microscopically and macroscopically and found that early osteoarthritic changes may only be detected microscopically [9, 21, 22]. Use of histological techniques could help affirm the “questionable OA” rating for the few specimens classified at that grade. However, as no mandibular fossae and only 4 of the 31 mandibular condyles (one younger female, two older females, and one older male) were graded as having questionable degenerative/osteoarthritic changes, microscopic or histologic evaluation is unlikely to have altered the statistical findings. Histological assessment could also allow investigators to begin to look deeper at the mechanism of pathogenesis by examining specific cells types and their presence/activation at particular ages and locations. Microscopic evaluation can increase the possible risk of overdiagnosis, so it is important to thoroughly assess specimens for gross signs of OA prior to harvest and sectioning for histology.

Several limitations regarding photography of the dissected TMJ components are also worth mentioning. One limitation was variability in lighting and shadowing captured in the photographs. Differences in background, location within the cadaver lab, and ambient lighting at

the time were all contributing factors. The degree of tissue drying, at what timepoint the TMJs could be harvested from each donor, and number of photographs taken per specimen varied as well. The consistency of the number of photographs and views per specimen was established with the latest cohort of donors as this study proceeded. A dedicated photography station with consistent regiment and background will aid in minimizing variability of photographs for future data collection.

### **Future Work**

As discussed briefly in the introduction, several past studies have examined a possible correlation between TMJ OA and tooth loss (especially of the molars and “lateral” teeth termed loss of “occlusal support”) [5-7, 10, 12, 16-19]. Tooth wear/attrition has also been evaluated in studies of both contemporary and archaeological specimens for a possible correlation to TMJ OA severity with mixed findings [15, 50]. Data on the state of dentition in the subjects used for this study were collected at the time of dissection and is intended to be used in a future study to evaluate for possible correlations to TMJ OA severity. A case report published using data from this study highlighted two cadavers with extremely severe TMJ OA. Both specimens demonstrated a high number of restored teeth and/or missing teeth [40]. Further investigation into the possible correlation between TMJ OA and the state of dentition will be continued with future data collection.

Additionally, TMJ disc pathology and displacement have been studied extensively in the context of TMJ OA and could serve as an avenue for continued research [5-12, 14, 16, 18, 20, 22, 23, 36, 42-45, 51-55]. TMJ articular discs with appropriate photography were examined in 30 of the 31 specimens used in this study; 17 of the 30 specimens (57%) showed visible signs of

degeneration. Although not statistically assessed in this study, disc pathology and displacement data can be further evaluated in detail and included in future studies.

Lastly, radiographic evaluation using cone-beam computed tomography (CBCT) of the cadaver specimens prior to dissection may be implemented in future portions of this study to produce additional data. Under the current donor program, specimens are not allowed to be removed from the cadaver lab. Additional donor programs and portable imaging equipment are being explored.

## **Conclusion**

Macroscopic evidence of OA was found in all 31 TMJs evaluated in this study with the mandibular fossae being equally or more affected than the mandibular condyle in 87% of the specimens. A disease severity scale (DSS) from grades 0 (no degenerative changes) to 4 (severe osteoarthritic changes) previously applied to other joints was utilized and its use for the evaluation of TMJs was validated, demonstrating high interrater reliability as measured by  $K\alpha$  testing. The average condyle DSS score was  $2.68 \pm 0.96$  and the average mandibular fossa score was  $2.90 \pm 0.76$  correlating with mild to moderate OA. No statistically significant correlation was found between TMJ OA severity and subject age or TMJ OA severity and subject gender. In reviewing published literature, there is a need for more research into the prevalence, pathological progression, and correlating factors of TMJ OA.

To the authors' knowledge, this study is the first to directly compare degenerative changes in the temporomandibular and knee joints of the same subjects and, in this small sample size, a correlation was found between the severity of OA in the femoral condyles and the mandibular fossae. Previous studies have shown a weak correlation between degenerative changes in the metatarsophalangeal joints and the TMJs in the same subjects, but no significant

correlation or mixed results when comparing the TMJs to the hand or sternoclavicular joints. It is hypothesized that this is due to the load-bearing function of the temporomandibular, knee, and metatarsophalangeal joints. Given the high comorbidity of TMJ disorders with general OA and this study's finding of a correlation between knee and TMJ OA, dental professionals should inquire about TMJD symptoms when patients present with a medical history including knee osteoarthritis or other joint problems of the lower extremities or spine. Awareness of the prevalence and severity of TMJ OA in the older population can assist dental professionals in early detection, diagnosis, and, if necessary, recommending appropriate conservative treatment options to their patients. Adequate attention and consideration should be given to signs and symptoms of parafunction in patients.

## Appendix A

### Permission to Use Copyrighted Material

University of Nevada, Las Vegas

I, **Jessica Immonen**, holder of copyrighted material entitled **Osteoarthritis Disease Severity in the Temporomandibular Joint and the Knee Joint: A Comparative Cadaveric Study**, authored by **Jessica Immonen, Jason Ciccotelli, Linh Nguyen, Lesley Gilmer, Landen Broadhead, Mackenzie Kitchen, Conner Paul and Jeremy James** originally published in *Cartilage*, **August 8, 2023**, hereby give permission for the author to use the above described material in total or in part for inclusion in a Master's thesis at the University of Nevada, Las Vegas.

I also agree that the author may execute the standard contract with ProQuest for storage and reproduction of the completed thesis, including the materials to which I hold copyright.

*Jessica Immonen*

February 2024

---

Signature

Date

Jessica Immonen

Associate Professor-in-Residence, Chair of Thesis Committee

---

Name (typed)

Title

## References

1. Standing, S., Anand, N., & Tunstall, R. (2021). *Gray's anatomy : the anatomical basis of clinical practice* (Forty-second edition..). Elsevier.
2. U.S. Department of Health and Human Services. (2018, July). *Facial pain*. National Institute of Dental and Craniofacial Research. Retrieved February 23, 2024, from <https://www.nidcr.nih.gov/research/data-statistics/facial-pain>
3. Valesan, L. F., Da-Cas, C. D., Réus, J. C., Denardin, A. C. S., Garanhani, R. R., Bonotto, D., Januzzi, E., & de Souza, B. D. M. (2021). Prevalence of temporomandibular joint disorders: a systematic review and meta-analysis. *Clinical Oral Investigations*, 25(2), 441–453. <https://doi.org/10.1007/s00784-020-03710-w>
4. Schiffman, E., Ohrbach, R., Truelove, E., Look, J., Anderson, G., Goulet, J.-P., List, T., Svensson, P., Gonzalez, Y., Lobbezoo, F., Michelotti, A., Brooks, S. L., Ceusters, W., Drangsholt, M., Ettlin, D., Gaul, C., Goldberg, L. J., Haythornthwaite, J. A., Hollender, L., Dworkin, S. F. (2014). Diagnostic Criteria for Temporomandibular Disorders (DC/TMD) for Clinical and Research Applications: recommendations of the International RDC/TMD Consortium Network and Orofacial Pain Special Interest Group. *Journal of Oral & Facial Pain and Headache*, 28(1), 6–27. <https://doi.org/10.11607/jop.1151>
5. Öberg, T., Carlsson, G. E., & Fajers, C.-M. (1971). The Temporomandibular Joint: A Morphologic Study on A Human Autopsy Material. *Acta Odontologica Scandinavica*, 29(3), 349–384. <https://doi.org/10.3109/00016357109026526>
6. Bauer, W. H. (1941). Osteo-arthritis deformans of the temporomandibular joint. *The American Journal of Pathology*, 17(1), 129.

7. Macalister, A. D. (1954). A microscopic survey of the human temporomandibular joint. *New Zealand Dental Journal*, 50, 161-172.
8. Blackwood, H. (1963). Arthritis of the mandibular joint. *British Dental Journal*, 115(8), 317-324.
9. Blackwood, H. J. J. (1969). Pathology of the temporomandibular joint. *The Journal of the American Dental Association*, 79(1), 118-124.
10. Luder, H.-U. (2002). Factors affecting degeneration in human temporomandibular joints as assessed histologically. *European Journal of Oral Sciences*, 110(2), 106–113.  
<https://doi.org/10.1034/j.1600-0722.2002.11212.x>
11. Westesson, P.-L., & Rohlin, M. (1984). Internal derangement related to osteoarthritis in temporomandibular joint autopsy specimens. *Oral Surgery, Oral Medicine, Oral Pathology*, 57(1), 17–22. [https://doi.org/10.1016/0030-4220\(84\)90251-2](https://doi.org/10.1016/0030-4220(84)90251-2)
12. Widmalm, S. E., Westesson, P.-L., Kim, I.-K., Pereira, F. J., Lundh, H., & Tasaki, M. M. (1994). Temporomandibular joint pathosis related to sex, age, and dentition in autopsy material. *Oral Surgery, Oral Medicine, Oral Pathology*, 78(4), 416–425.  
[https://doi.org/10.1016/0030-4220\(94\)90031-0](https://doi.org/10.1016/0030-4220(94)90031-0)
13. Ishibashi, H., Takenoshita, Y., Ishibashi, K., & Oka, M. (1995). Age-related changes in the human mandibular condyle: A morphologic, radiologic, and histologic study. *Journal of Oral and Maxillofacial Surgery*, 53(9), 1016–1023. [https://doi.org/10.1016/0278-2391\(95\)90117-5](https://doi.org/10.1016/0278-2391(95)90117-5)
14. Åkerman, S., Rohlin, M., & Kopp, S. (1984). Bilateral degenerative changes and deviation in form of temporomandibular joints An autopsy study of elderly individuals. *Acta*



*Odontologica Scandinavica*, 42(4), 205–214.

<https://doi.org/10.3109/00016358408993873>

15. Magnusson, C., Ernberg, M., & Magnusson, T. (2008). A description of a contemporary human skull material in respect of age, gender, temporomandibular joint changes, and some dental variables. *Swedish Dental Journal*, 32(2), 69.
16. Axelsson, S., Fitins, D., Hellsing, G., & Holmlund, A. (1987). Arthrotic changes and deviation in form of the temporomandibular joint--an autopsy study. *Swedish Dental Journal*, 11(5), 195-200.
17. Rohlin, M., Åkerman, S., & Kopp, S. (1986). Tomography as an aid to detect macroscopic changes of the temporomandibular joint An autopsy study of the aged. *Acta Odontologica Scandinavica*, 44(3), 131–140.  
<https://doi.org/10.3109/00016358609026565>
18. Toure, G., Duboucher, C., & Vacher, C. (2005). Anatomical modifications of the temporomandibular joint during ageing. *Surgical and Radiologic Anatomy (English Ed.)*, 27(1), 51–55. <https://doi.org/10.1007/s00276-004-0289-0>
19. Magnusson, C., Nilsson, M., & Magnusson, T. (2010). Degenerative changes in human temporomandibular joints in relation to occlusal support. *Acta Odontologica Scandinavica*, 68(5), 305–311. <https://doi.org/10.3109/00016357.2010.494623>
20. Castelli, W. A., Nasjleti, C. E., Diaz-Perez, R., & Caffesse, R. G. (1985). Histopathologic findings in temporomandibular joints of aged individuals. *The Journal of Prosthetic Dentistry*, 53(3), 415–419. [https://doi.org/10.1016/0022-3913\(85\)90525-6](https://doi.org/10.1016/0022-3913(85)90525-6)

21. Flygare, L., Rohlin, M., & Åkerman, S. (1992). Macroscopic and microscopic findings of areas with radiologic erosions in human temporomandibular joints. *Acta Odontologica Scandinavica*, *50*(2), 91–100. <https://doi.org/10.3109/00016359209012751>
22. De Bont, L. G. M., Boering, G., Liem, R. S. B., Eulderink, F., & Westesson, P.-L. (1986). Osteoarthritis and internal derangement of the temporomandibular joint: a light microscopic study. *Journal of Oral and Maxillofacial Surgery*, *44*(8), 634–643. [https://doi.org/10.1016/S0278-2391\(86\)80075-1](https://doi.org/10.1016/S0278-2391(86)80075-1)
23. Pereira, F. J., Lundh, H., & Westesson, P.-L. (1994). Morphologic changes in the temporomandibular joint in different age groups: An autopsy investigation. *Oral Surgery, Oral Medicine, Oral Pathology*, *78*(3), 279–287. [https://doi.org/10.1016/0030-4220\(94\)90055-8](https://doi.org/10.1016/0030-4220(94)90055-8)
24. Safiri, S., Kolahi, A. A., Smith, E., Hill, C., Bettampadi, D., Mansournia, M. A., Hoy, D., Ashrafi-Asgarabad, A., Sepidarkish, M., Almasi-Hashiani, A., Collins, G., Kaufman, J., Qorbani, M., Moradi-Lakeh, M., Woolf, A. D., Guillemin, F., March, L., & Cross, M. (2020). Global, regional and national burden of osteoarthritis 1990-2017: a systematic analysis of the Global Burden of Disease Study 2017. *Annals of the rheumatic diseases*, *79*(6), 819–828. <https://doi.org/10.1136/annrheumdis-2019-216515>
25. Centers for Disease Control. (2020). A National Public Health Agenda for Osteoarthritis: 2020 Update. <https://www.cdc.gov/arthritis/docs/oaagenda2020.pdf>
26. Song, H.-S., Shin, J.-S., Lee, J., Lee, Y. J., Kim, M.-R., Cho, J.-H., Kim, K.-W., Park, Y., Song, H. J., Park, S.-Y., Kim, S., Kim, M., & Ha, I.-H. (2018). Association between temporomandibular disorders, chronic diseases, and ophthalmologic and otolaryngologic

- disorders in Korean adults: A cross-sectional study. *PloS One*, 13(1), e0191336–e0191336. <https://doi.org/10.1371/journal.pone.0191336>
27. Yost, O., Liverman, C. T., English, R., Mackey, S., Bond, E. C., & National Academies of Sciences, Engineering, and Medicine. (2020). Individual and Societal Burden of TMDs. In *Temporomandibular Disorders: Priorities for Research and Care*. National Academies Press (US).
28. World Health Organization: WHO. (2023, July 14). *Osteoarthritis*. Retrieved February 23, 2024, from <https://www.who.int/news-room/fact-sheets/detail/osteoarthritis>
29. Zhang, X., Chen, F., Chen, L., Li, B., Xu, S., Cui, D., Yu, L., Liu, M., Shi, X., Li, Q., & Li, Y. (2017). Symptoms and signs of temporomandibular disorders in patients with knee osteoarthritis. *International Dental Journal*, 67(2), 78–84. <https://doi.org/10.1111/idj.12262>
30. Ericson, S., & Lundberg, M. (1968). Structural changes in the finger, wrist and temporomandibular joints: A Comparative radiologic study. *Acta Odontologica Scandinavica*, 26(1-2), 111–126. <https://doi.org/10.3109/00016356809004584>
31. Kopp, S., Carlsson, G. E., Hansson, T., & Öberg, T. (1976). Degenerative disease in the temporomandibular, metatarsophalangeal and sternoclavicular joints An autopsy study. *Acta Odontologica Scandinavica*, 34(1), 23–32. <https://doi.org/10.3109/00016357609026555>
32. Kopp, S., & Rockler, B. (1979). Relationship between radiographic signs in the temporomandibular joint and hand joints. *Acta Odontologica Scandinavica*, 37(3), 169–175. <https://doi.org/10.3109/00016357909004692>

33. Wolf, J., Könönen, M., & Mäkilä, E. (1995). Radiographic signs in the TMJ and finger joints in elderly people. *Journal of Oral Rehabilitation*, 22(4), 269–274.  
<https://doi.org/10.1111/j.1365-2842.1995.tb00085.x>
34. Abrahamsson, A., Kristensen, M., Arvidsson, L. Z., Kvien, T. K., Larheim, T. A., & Haugen, I. K. (2017). Frequency of temporomandibular joint osteoarthritis and related symptoms in a hand osteoarthritis cohort. *Osteoarthritis and Cartilage*, 25(5), 654–657.  
<https://doi.org/10.1016/j.joca.2016.12.028>
35. Immonen, J. A., Ciccotelli, J., Nguyen, L. M., Gilmer, L., Broadhead, L., Kitchen, M., Paul, C., & James, J. (2023). Osteoarthritis Disease Severity in the Temporomandibular Joint and the Knee Joint: A Comparative Cadaveric Study. *Cartilage*, 14(4), 445–454.  
<https://doi.org/10.1177/19476035231189839>
36. Luder, H. U. (1993). Articular degeneration and remodeling in human temporomandibular joints with normal and abnormal disc position. *Journal of Orofacial Pain*, 7(4), 391–402.
37. Kovler, M., Lundon, K., McKee, N., & Agur, A. (2004). The human first carpometacarpal joint: Osteoarthritic degeneration and 3-dimensional modeling. *Journal of Hand Therapy*, 17(4), 393–400. <https://doi.org/10.1197/j.jht.2004.07.001>
38. Byers, P. D., Contepomi, C. A., & Farkas, T. A. (1970). A post mortem study of the hip joint. Including the prevalence of the features of the right side. *Annals of the Rheumatic Diseases*, 29(1), 15–31. <https://doi.org/10.1136/ard.29.1.15>
39. Immonen, J., Stevens, K., Albin, A., Chaus, D., Gilmer, L., & Zdilla, M. (2021). Assessment of the Degree of Osteoarthritis in Aging Male and Female Femoral Condyles: A Cadaveric Study. *Cartilage*, 13(1\_suppl), 1684S–1695S.  
<https://doi.org/10.1177/1947603520916530>

40. Immonen, J. A., Robinson, W. C., Melocoton, M., Friesen, P., Ren, Y., & James, J. (2023). Temporomandibular Joint Osteoarthritis Exacerbates with Restored Teeth: A Cadaveric Case Report. *Open Access Journal of Dental Sciences*, 8(2).  
<https://doi.org/10.23880/oajds-16000365>
41. Immonen, J., Patterson, D., Kent, N., Pipkin, S., Luu, A., Nguyen, L. M., Ciccotelli, J., & James, J. (2024). Biomechanics of Bruxism Determine the Sites of Severe TMJ Osteoarthritis. *Biomechanics*. *In press*
42. Bean, L. R., Omnell, K. A., & Oberg, T. (1977). Comparison between radiologic observations and macroscopic tissue changes in temporomandibular joints. *Dento-Maxillo-Facial Radiology*, 6(2), 90–106. <https://doi.org/10.1259/dmfr.1977.0014>
43. Nannmark, U., Sennerby, L., & Haraldson, T. (1990). Macroscopic, microscopic and radiologic assessment of the condylar part of the TMJ in elderly subjects. An autopsy study. *Swedish Dental Journal*, 14(4), 163-169.
44. Pereira, F. J., Lundh, H., Westesson, P.-L., & Carlsson, L.-E. (1994). Clinical findings related to morphologic changes in TMJ autopsy specimens. *Oral Surgery, Oral Medicine, Oral Pathology*, 78(3), 288–295. [https://doi.org/10.1016/0030-4220\(94\)90056-6](https://doi.org/10.1016/0030-4220(94)90056-6)
45. Hansson, T., & Öberg, T. (1977). Arthrosis and deviation in form in the temporomandibular joint A macroscopic study on a human autopsy material. *Acta Odontologica Scandinavica*, 35(1-3), 167–174. <https://doi.org/10.3109/00016357709056006>
46. Okeson, J. P. (2019). *Management of temporomandibular disorders and occlusion* (8th ed.). Mosby.

47. Perez Del Palomar, Ap., & Doblare, M. (2006). Finite element analysis of the temporomandibular joint during lateral excursions of the mandible. *Journal of Biomechanics*, 39(12), 2153–2163. <https://doi.org/10.1016/j.jbiomech.2005.06.020>
48. Sagl, B., Schmid-Schwab, M., Piehslinger, E., Kundi, M., & Stavness, I. (2022). Effect of facet inclination and location on TMJ loading during bruxism: An in-silico study. *Journal of Advanced Research*, 35, 25–32. <https://doi.org/10.1016/j.jare.2021.04.009>
49. Zhao, Y., & Ye, D. (1994). Measurement of biting force of normal teeth at different ages. *Hua xi yi ke da xue xue bao= Journal of West China University of Medical Sciences= Huaxi Yike Daxue Xuebao*, 25(4), 414-417.
50. Eversole, L. R., Pappas, J. R., & Graham, R. (1985). Dental occlusal wear and degenerative disease of the temporomandibular joint: a correlational study utilizing skeletal material from a contemporary population. *Journal of Oral Rehabilitation*, 12(5), 401–406. <https://doi.org/10.1111/j.1365-2842.1985.tb01545.x>
51. Akerman, S., Kopp, S., & Rohlin, M. (1988). Macroscopic and microscopic appearance of radiologic findings in temporomandibular joints from elderly individuals: an autopsy study. *International Journal of Oral and Maxillofacial Surgery*, 17(1), 58–63. [https://doi.org/10.1016/S0901-5027\(88\)80232-7](https://doi.org/10.1016/S0901-5027(88)80232-7)
52. Grunert, I., Grubwieser, G. J., & Ulmer, H. (2000). Bilateral investigation of the temporomandibular joint. An autopsy study of edentulous individuals. *Journal of Oral Rehabilitation*, 27(8), 671–681. <https://doi.org/10.1046/j.1365-2842.2000.00559.x>
53. Honda, K., Larheim, T. A., Sano, T., Hashimoto, K., Shinoda, K., & Westesson, P. L. (2001). Thickening of the glenoid fossa in osteoarthritis of the temporomandibular joint. An

autopsy study. *Dento-Maxillo-Facial Radiology*, 30(1), 10–13.

<https://doi.org/10.1038/sj.dmfr.4600559>

54. Rohlin, M., Westesson, P.-L., & Eriksson, L. (1985). The correlation of temporomandibular joint sounds with joint morphology in fifty-five autopsy specimens. *Journal of Oral and Maxillofacial Surgery*, 43(3), 194–200. [https://doi.org/10.1016/0278-2391\(85\)90159-4](https://doi.org/10.1016/0278-2391(85)90159-4)
55. Widmalm, S.-E., Westesson, P.-L., Brooks, S. L., Hatala, M. P., & Paesani, D. (1992). Temporomandibular joint sounds: Correlation to joint structure in fresh autopsy specimens. *American Journal of Orthodontics and Dentofacial Orthopedics*, 101(1), 60–69. [https://doi.org/10.1016/0889-5406\(92\)70083-M](https://doi.org/10.1016/0889-5406(92)70083-M)

## Curriculum Vitae

Jeremy James

---

Email: jeremykjame808@gmail.com

### Education:

Bachelor of Science – Exercise Science and Japanese, 2013  
Brigham Young University, Provo, Utah

Bachelor of Science – Biology, 2016  
Utah Valley University, Orem, Utah

Doctor of Dental Medicine, 2021  
University of Nevada, Las Vegas

### Thesis Title:

Osteoarthritis in the Temporomandibular Joint and Knee Joint: A Macroscopic study in Cadaver Specimens

### Thesis Examination Committee:

Chairperson, Jessica Immonen, Ph.D., M.S.

Committee Member, Linh Nguyen, Ph.D., M.P.H.

Committee Member, Karl Kingsley, Ph.D., M.P.H.

Committee Member, Brian Chrzan, D.D.S., Ph.D.

Graduate Faculty Representative, Erika Marquez, Ph.D., M.P.H.

Graduate Coordinator, Brian Chrzan, D.D.S., Ph.D.